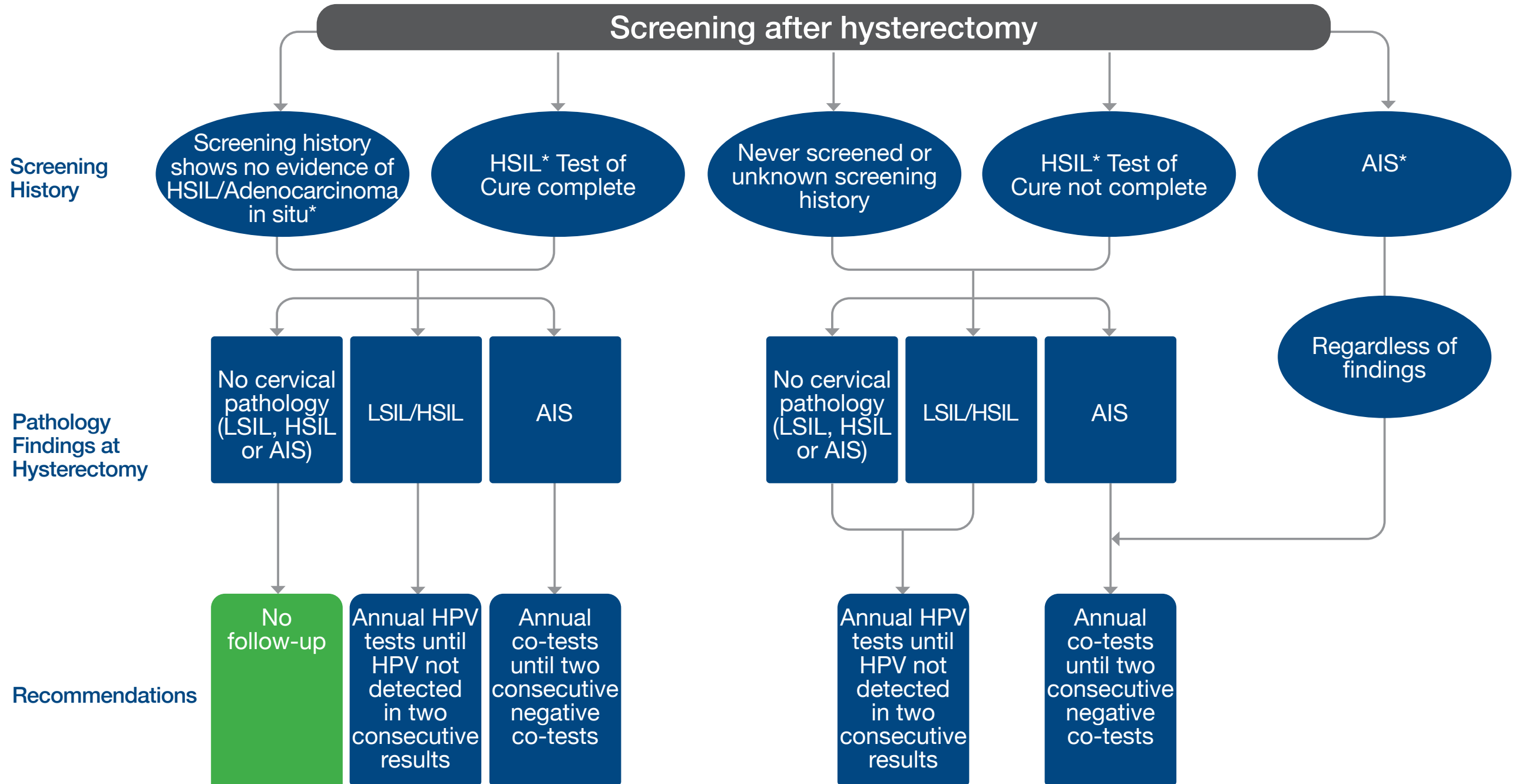


SCREENING AFTER HYSTERECTOMY



* Histologically confirmed
 LSIL = Low-grade squamous intraepithelial lesion
 HSIL = High-grade squamous intraepithelial lesion
 AIS = Adenocarcinoma in situ